

# The ALF (Advanced Lightwire Functional Appliance) Creating Facial Beauty and Balance

By Edwin Delz, DDS

*Abstract: Adult orthopedic and orthodontic treatment requires a more circumspect sensibility in diagnosis, technology selection, reasons for treatment, and patient goals. Many adults present with asymmetries of the dental arches, the cranium, and the entire body. The use of the (ALF) Advanced Lightwire Functional appliance for adult orthopedic treatment will be shown. The appliance construction, application, rational, indications for use, and the results of adding this appliance to an adult treatment regimen will be explored.*

## Introduction

Dr. John Witzig was the father of functional appliances in the United States and he engrained in us, his students, the appreciation for and use of functional appliances that assisted in the growth, development, and remodeling of the dental arches. The results he achieved with functional appliances sometimes precluded the use of brackets and wires.

The use of these same acrylic appliances shown in Figures 1 and 2 in the treatment of adults became a compliance issue and their use, in my opinion, was a failure. The appliances were an exercise in futility rather than an adjunct to successful treatment. In many cases, when the acrylic appliances were replaced with ALF (Advanced Lightwire Functional) appliances, compliance improved. The ALF appliances are invisible in the mouth, unobtrusive, do not impair speech, and can be worn 24 hours a day and 7 days a week. Their effectiveness in assisting the brackets and wires in the

orthopedic process of realignment became apparent after a short period of time.

My introduction to the use of the ALF appliance was for a dental purpose with an intention to move teeth. I had used the ALF for three years prior to attending the James and Strokon Seminar. Their seminar and the articles they have written for this journal,<sup>1-10</sup> created a whole new dimension in my ALF education with respect to the use of the ALF for the Osteopathic correction of the cranial asymmetries that are present in our patients. I recommend that any dentist that aspires to implement the use of the ALF read and digest each article in previous Journals. In their course manual James and Strokon stated, "Firstly, this appliance is designed primarily to assist in the correction of cranial 'lesions' and only secondarily to move teeth."<sup>1</sup> It is the impression of this author that cranial distortions and tooth arrangement issues will occur in conjunction with each other.

The use of the appliance invites the user to investigate from both directions. If one waits to learn a technique until all current knowledge is understood, one loses the opportunity to perfect the use of the appliances.

## Structural Elements

The ALF is constructed from .025 Elgiloy wire. It is a very flexible and resilient wire which applies light forces to the teeth. The appliance consists of a .025 Elgiloy lingual wire that extends around the lingual surface of the arch from molar to molar. Omega loops are bent into the arch wire where expansion or spacing is desired. Crescents are soldered to the wire to assist in retention

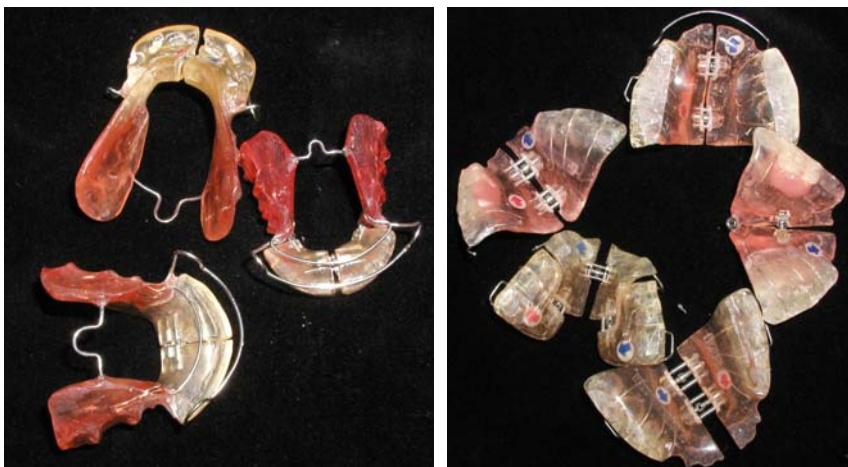

Figure 1&2 - Functional Acrylic Appliances

of the appliance in the premaxillary area. Wire cribs create positive retention on the molars and can be designed for specific molar movement. Bonded composite can be placed on various teeth to increase appliance retention. Finger springs can be added at the distal ends of the wire to distalize second molars. Individual loops can be used to create specific molar movements. An examination of the structural elements would indicate that the ALF is a combination of many appliances all wrapped into one appliance.

In Figure 3 and 4 the structural elements are labeled as the functional effects they induce.

### CREATION and PHILOSOPHY

The ALF appliance is the brain child of Darick Nordstrom, DDS. ALF treatment involves the gentle harnessing or redirecting of muscle parafunction to resolve skeletal problems.<sup>11</sup> This technique evolved from other proven designs for over a decade while Dr. Nordstrom was working hand in hand with physicians, therapists and a very talented technician.

Dr. Nordstrom stated, "Applying the principles of ALF philosophy to an orthodontic treatment plan will simplify attaining the treatment goals of a stable, self maintaining occlusion." Dr Nordstrom stated the ALF

Philosophy as follows:

1. Forces should mimic or be similar to those of the tongue in the mature, tooth-together swallowing reflex.
2. Appliances should be minimally intrusive on the intra-oral function.
3. Stable completion requires a mature swallow defined by: correct vertical dimension and tongue space with well functioning TMJ's.
4. Correct location of premaxilla, with anterior coupling, and nasal breathing, release of dento-cranial lesions, and establishment of resilient cranial motion.
5. Disease-free dentition in organic occlusion.<sup>1</sup>

The ALF facilitates the remodeling of the maxilla and mandible to what might have been their genetically predetermined position. "During development, balance is continuously transient and can never actually be achieved because growth itself constantly creates ongoing normal regional imbalances."<sup>12</sup> The sources of imbalance in growth and development can be attributed to the brain, the basicranium, the airway, and growth of the oral region.<sup>13</sup> Breathing, the infantile swallow, cranial distortions, oral habits, and all the other critical events that human beings go through can also interfere with normal growth and development.

The patient in Figure 5 presented with evidence of all the above listed issues and was treated with ALF appliances, brackets, and wires.

### DIAGNOSIS AND TREATMENT

The new user may view the appliance as complicated, difficult to learn, and properly design. The ability to visualize the three dimensions of their patient comes through the use of mounted models, x-rays, and photos of the patient. The appliance designs itself based upon the distortions in arch shape and form that are present at the start of the case and on the desired results at the end of the case. These arch, cranial, and body distortions will usually be where there is a lack of harmony in the alignment of the eye plane, the ear plane, the occlusal plane, vertical plane, and the symmetry of the right and left sides of the face.

Figure 6 demonstrates these various planes and their relationships.

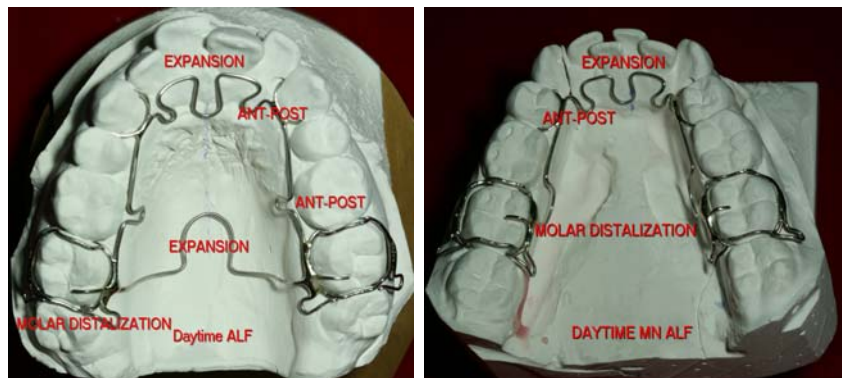


Figure 3&4 - Structural Elements and Functional Effects

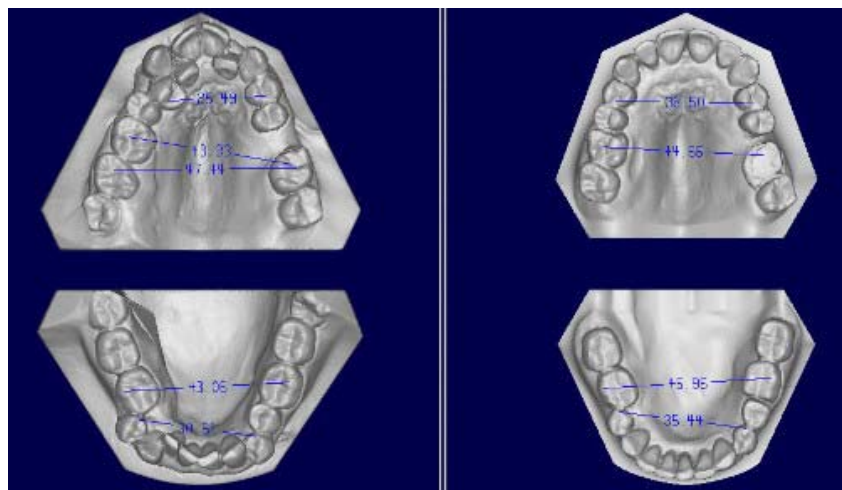


Figure 5 - Before and After

Continued use of the ALF appliance over many patients lead the user to get a sense that the ALF with only light forces cannot be physically having any effect, but it is! Could it be that the ALF just frees up the cranial bones and they begin to self correct and return to a state of harmony with each other? Maybe the changes that become evident are a combination of both genetics and remodeling.

### TREATMENT SAFETY

The ALF is probably the safest functional appliance to use because the light forces will not be able to overwhelm the boney arches. Dr. Gerald Smith noted in his article that the physiologic action of the ALF appliance is consistent with the

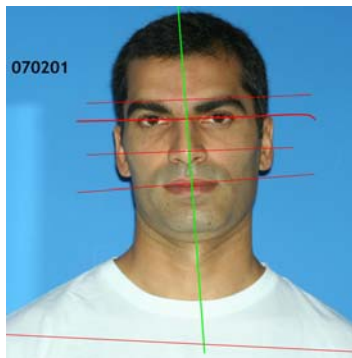


Figure 6 - Asymetrical Facial Planes

Arndt-Schulz Law: "Weak stimuli increase physiological activity and very strong stimuli inhibit or abolish activity."<sup>14</sup> These forces are applied at the cervical line and thus closer to the center of resistance of the teeth. This centered connection produces more bodily movement of the teeth rather than tipping of the teeth.

The use of the ALF is like getting a new gift each time you see the patient. You will have your preferences of results you would like to see. The ALF will present you with those desired results and a bonus gift of results that were not expected but were the result of the actions of the appliance itself. In Figure 7 the original result desired was to move teeth and the surprise result was the remodeling of the maxilla from a narrow arch to a rounded arch and a pleasant smile.

### DENTAL ARCH REMODELING

Each tooth becomes a handle that transfers the force of the appliance and muscle function to the maxilla and the mandible. These light forces on the teeth cause the maxilla and mandible to undergo a remodeling and a reshaping of the dental arch. The reshaping of the premaxilla occurs at the sutures and the alveolar bone.<sup>13</sup>

Upledger et al. "demonstrated the presence of viable myelinated and unmyelinated nerve fibers, nerve receptor endings, a potentially functional vascular system, and collagen elastic fiber complexes within the human cranial sutures."<sup>15</sup> The significance of those findings is that now the human cranial sutures may be considered as a functional anatomical complex capable of dysfunction resultant to various imbalances, stresses, and trauma."<sup>15</sup>

The expansion in the premaxilla can be very substantial as shown in Figures 5 and 7. Reshaping of the mandible seems to occur within the alveolar bone. Figure 8 demonstrates the reshaping of a mandibular arch and the realignment of the teeth from start to finish.

Figure 9 demonstrates realignment of the teeth and distalization of the molars to create room for implants and CEREC® crowns.

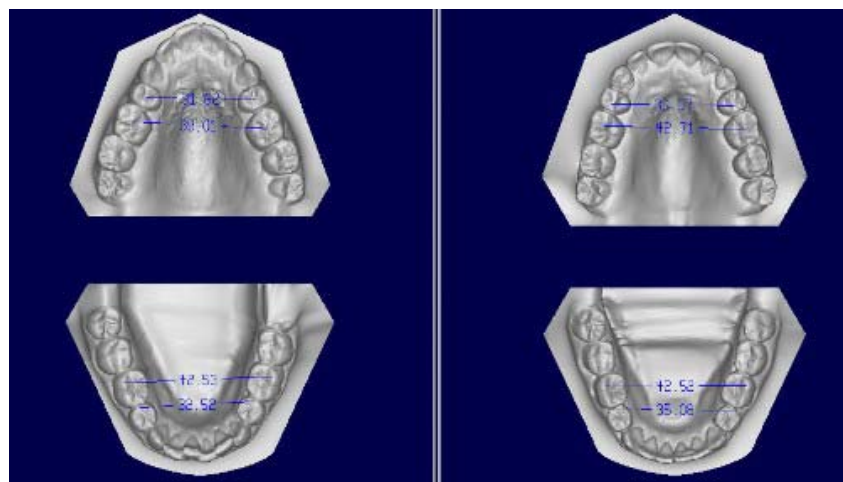


Figure 7 - Arch Remodeling

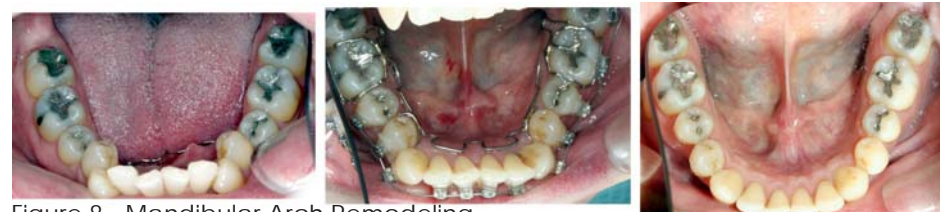

Figure 8 - Mandibular Arch Remodeling

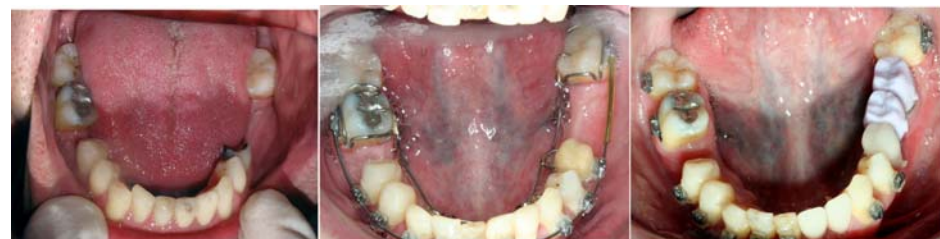

Figure 9 - Mandibular Realignment and Molar Distalization

## “Sphenoid-Occipital Paradox”

The paradox is that these two bones can have a protective influence and a destructive influence on an individual. If we examine the bones of the cranium and relate them to the areas of the brain and spinal cord that they enclose, we can see what we didn't know that we did not know even though it has always been right in front of us.

Most bones of the skull are paired right and left and during the birthing process as the fetal head approaches the pelvic opening in a process called “molding”<sup>16</sup> these paired cranial bones overlap in order to pass through the birth canal. Two important bones, the sphenoid and occipital bones, are not paired. They form the middle and posterior cranial base, they are connected at the spheno-occipital synchondrosis, and they both cross the midline as a flexible unit. The foramen magnum passes through the occipital bone and the sphenoid bone houses the pituitary gland in the pituitary fossa. These two bones function during the birthing process to support and protect the brain and spinal cord connection and prevent damage to the sensitive nerve tissue at that connection. If these two bones do not realign properly after birth and the distortion does not self correct, it can remain locked in for life. Frymann in a study of 1250 newborns found cranial distortions in 95% of the newborns.<sup>17</sup> These fetal misalignments can perpetuate the distortion into the adult head form, the dental arches, and the body.

The realignment of the supporting bones of the skull and oral facial complex restores symmetry and provides a framework for the soft tissues of the facial form. The end result is a more appropriate facial balance as seen in Figures 10 and 11.

## HEAD WEIGHT AND BODY ASYMMETRY

Body asymmetry that was the result of cranial distortion and the body's attempt to center head weight will respond by cranial realignment resulting from the use of ALF appliances. The head and shoulder alignment will improve and become more centered. That centered realignment will affect the entire body. The patient will become taller, the shoulders will realign, the hips will realign and the patient's posture will improve. The results you never expected could be the relief of TMJ's, headaches, the ability to walk and more effectively, improve

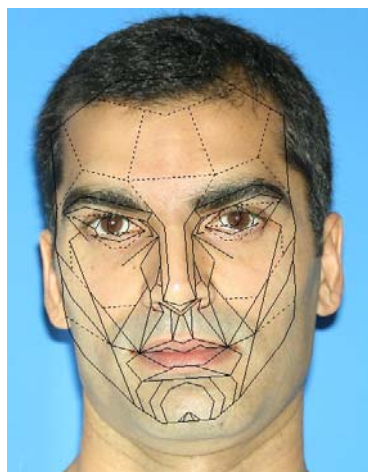


Figure 10 - Facial Mask Before ALF Treatment

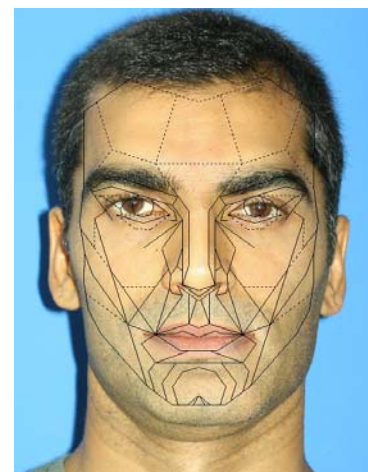


Figure 11 - Facial Mask After ALF Treatment

competitive swimming event times, and other patient body issues.

See Figures 12, and 13 and note body realignment.

## Conclusions

Many adults enter our practices with multiple tooth, arch, and cranial defects. They have a short tolerance time for wearing functional and/or fixed orthodontic appliances. The ALF (Advanced Lightwire Functional Appliance) may create the possibility of augmenting, enhancing, and decreasing the length of orthodontic treatment. These appliances are well tolerated by adults since they can be removed and inserted at the discretion of the patient themselves and allow them some treatment freedom in their business and social lives.




Figure 12 - Body Asymmetry Before ALF Treatment




Figure 13 - Body Realignment After ALF Treatment

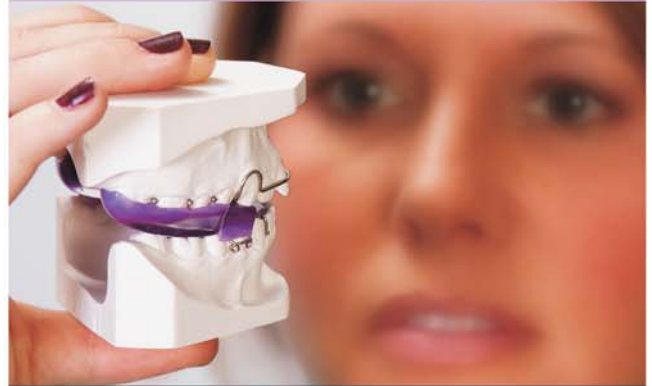## References

1. James, Strokon Seminars, Course Manual, "The Advanced Lightwire Functional (A.L. F) Appliance And Cranial Bio-Mechanics, Seminar 1, 2001."
2. James, G.A., Strokon, D. "The Significance of Cranial Factors in Diagnosis and Treatment with the Advanced Lightwire Functional Appliance." *Int. J. Orthodontics* 14:3:17-23:2005.
3. James, G.A., Strokon, D. "An Introduction To Cranial Movement and Orthodontics." *Int. J. Orthodontics* 16:1:23-29:2005.
4. James, G.A., Strokon, D. "Cranial Strains and Malocclusion: A Rationale for a New Diagnostic and Treatment Approach." *Int. J. Orthodontics* 16:2:25-29:2005.
5. James, G.A., Strokon, D. "Cranial Strains and Malocclusion II Hyperflexion and Superior Vertical Strain." *Int. J. Orthodontics* 16:3:15-19:2005.
6. James, G.A., Strokon, D. "Cranial Strains and Malocclusion: III Inferior Vertical Strain." *Int. J. Orthodontics* 16:4:21-29:2005.
7. James, G.A., Strokon, D. "Cranial Strains and Malocclusion: Torsion IV." *Int. J. Orthodontics* 17:1:19-24:2006.
8. James, G.A., Strokon, D. "Cranial Strains and Malocclusion: V Side Bend-Part 1." *Int. J. Orthodontics* 17:2:19-23 2006
9. James, G.A., Strokon, D. "Cranial Strains and Malocclusion: VI Side Bend-Part 2" *Int. J. Orthodontics* 17:3:35-39 2006
10. James, G.A., Strokon, D. "Cranial Strains and Malocclusion VII: A Review." *Int. J. Orthodontics* 17:4:23-28:2006.
11. Nordstrom, Darick: "Positive Alveolar and Gingival Effects of the ALF LB," *The Functional Orthodontist*, Vol. 13 No. 5, 1996.
12. Enlow, Donald H.: *Essentials of Facial Growth*, W.B. Saunders, Philadelphia, Pa. 1996 pg. 2.
13. Enlow, Donald H.: *Essentials of Facial Growth*, W.B.Saunders, Philadelphia, Pa. 1996 pg. 11-14.
14. Smith, Gerald & Aston, Heather: "ALF Appliance Design Conforms to Functional Cranial Anatomy," *The Functional Orthodontist*, Vol. 13, No. 2, 1996.
15. Upledger, John E., Retzlaff, Ernest E. "Diagnosis and Treatment of Temporoparietal Suture Head Pain." *Osteopathic Medicine*, July 1978:19-23.
16. Berthe, Jose MD-OBGYN, Personal Communication.
17. Frymann, V. "Relationship of Disturbances of Cranialsacral Mechanism to Symptomatology of Newborn. Study of 1250 Infants." *J.A.O.A* 65:1059-1075: 1966.



*Dr. Delz received his B.S. form the University of Florida and his D.D.S. from Fairleigh Dickinson Dental School. He interned at Hackensack Hospital in N.J. and completed an anesthesia residency at Long Island Jewish Hospital. Dr. Delz received his Fellowship in anesthesia from the ADSA and he is a Certified Senior Instructor in the IAO. Dr. Delz uses the ALF appliance to facilitate correction of craniofacial asymmetries and has applied the physics principles employed in Aikido for tooth movement. Dr. Delz can be contacted at drdelz@bellsouth.net.*

# "Remake" is a bad word at Johns Dental.



Lisa, one of our ortho technicians, is shown checking the bite on a twin block appliance before it moves on for final inspection.

## We measure quality by our remake percentage.

When we remake a case it costs us time, materials and profit, but we know it costs you that and more! That's why we check all of our cases multiple times throughout the fabrication process.

## We take quality very seriously.

With over 70 years in the dental business and well over 1,700 years of combined experience among our lab technicians, we pride ourselves in getting your case right the first time.

## Our technicians sign their work.

A quality inspection card, initialed by the master technician and final inspector, is included with every case.



Appliances & Prosthetics that Fit Right the First time!

Terre Haute, IN 800/457-0504 [www.johnsdental.com](http://www.johnsdental.com)

TMJ SPLINTS • SLEEP APNEA • CEPH TRACINGS • ORTHO • CROWN & BRIDGE • DENTURE & PARTIAL DENTURE